

# Managing Incidental Findings on Abdominal and Pelvic CT and MRI, Part 3: White Paper of the ACR Incidental Findings Committee II on Splenic and Nodal Findings

Matthew T. Heller, MD<sup>a</sup>, Mukesh Harisinghani, MD<sup>b</sup>, Jeffrey D. Neitlich, MD<sup>c</sup>, Paula Yeghiayan, MD<sup>d</sup>,  
Lincoln L. Berland, MD<sup>e</sup>

This white paper describes splenic and nodal incidental findings found on CT and MRI. Recommendations for management are included. This represents the third of 4 such papers from the ACR Incidental Findings Committee II, which used a consensus method based on repeated reviews and revisions and a collective review and interpretation of relevant literature. Topics include descriptions of appearances of several types of splenic lesions and, the importance of size and distribution of lymph nodes. Flowcharts are provided for reference.

**Key Words:** Incidental findings, incidentaloma, ACR, consensus, CT, MRI, splenic lesion, adenopathy

*J Am Coll Radiol* 2013;10:833-839. Copyright © 2013 American College of Radiology

## FOREWORD

This white paper does not comprehensively review the interpretation and management of cystic and solid masses in the spleen and lymph nodes, but it provides general guidance for managing common, incidental findings on CT and MRI, appreciating that individual care will vary depending on each patient's specific circumstances, the clinical environment, available resources, and the judgment of the practitioner. Also, the term *guidelines* has not been used in this or the prior white papers to avoid the implication that these represent com-

ponents of the ACR Practice Guidelines and Technical Standards (which represent official ACR policy, having undergone a rigorous drafting and review process culminating in approval by the ACR Council), or the ACR Appropriateness Criteria<sup>®</sup> (which use a formal consensus-building approach using a modified Delphi technique). This white paper, which represents the collective experience of the ACR Incidental Findings Committee II, was developed through a less formal process of repeated reviews and revisions of the draft document and does not represent official ACR policy. For these reasons, this white paper should not be used to establish the legal standard of care in any particular situation.

## INTRODUCTION

Please refer to the overview of the work of the Incidental Findings Committee II [1] for a description of the purposes, structure and process, and the conventions used in these 4 white papers, of which this is the third. The authors of this white paper represent the spleen and lymph node subcommittee membership as listed in the appendix. The roster of the entire Incidental Findings Committee II is listed in the appendix of the overview of this project at <http://dx.doi.org/10.1016/j.jacr.2013.05.012>.

## INCIDENTAL SPLENIC FINDINGS

Most incidentally discovered splenic masses are benign and are of no clinical importance [2-4], but the imaging

Credits awarded for this enduring activity are designated "SA-CME" by the American Board of Radiology (ABR) and qualify toward fulfilling requirements for Maintenance of Certification (MOC) Part II: Lifelong Learning and Self-assessment.

<sup>a</sup>Department of Radiology, University of Pittsburgh School of Medicine and Medical Center, Pittsburgh, Pennsylvania.

<sup>b</sup>Department of Radiology, Massachusetts General Hospital, Harvard Medical School, Boston, Massachusetts.

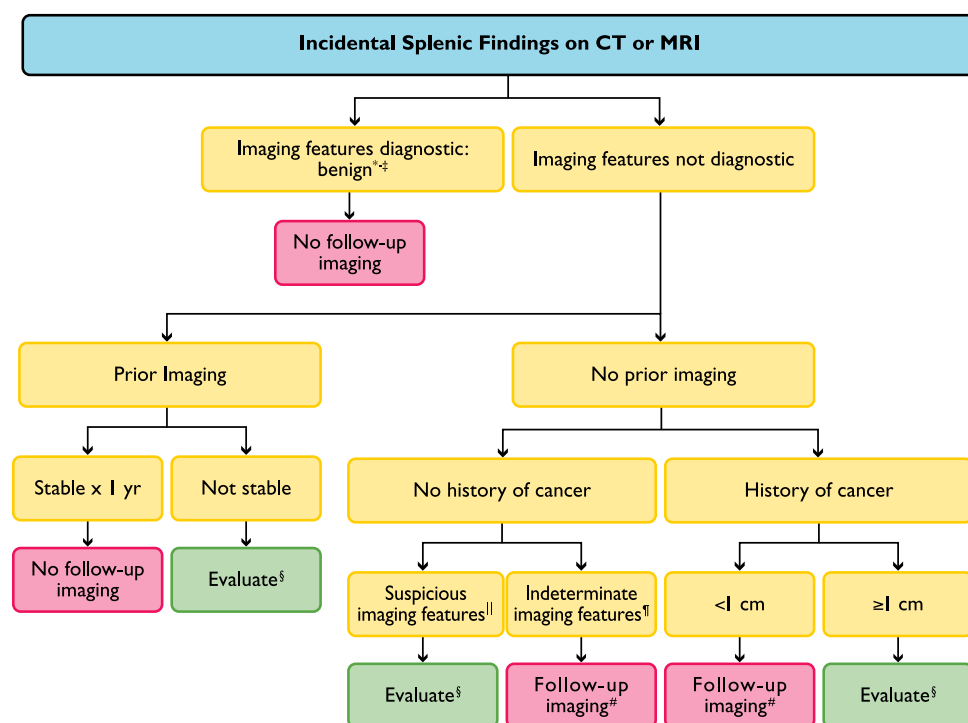
<sup>c</sup>Department of Radiology, Third Eye Teleradiology, Sequim, Washington.

<sup>d</sup>Department of Radiology, Wyckoff Heights Medical Center, Brooklyn, New York.

<sup>e</sup>Department of Radiology, University of Alabama at Birmingham, Birmingham, Alabama.

Corresponding author and reprints: Lincoln L. Berland, MD, Department of Radiology, University of Alabama at Birmingham, 619 S. 19th St., N454, Birmingham, AL 35249; e-mail: [lberland@uabmc.edu](mailto:lberland@uabmc.edu).

Disclosures: Dr Berland receives consulting fees from Nuance, Inc.



**Fig 1.** \*Cyst: imperceptible wall, near-water attenuation (<10 HU), no enhancement. †Hemangioma: discontinuous, peripheral, centripetal enhancement (findings that are uncommon in splenic hemangiomas). ‡Benign imaging features: homogeneous, low attenuation (<20 HU), no enhancement, smooth margins. §Evaluate: PET vs. MRI vs. biopsy. ||Suspicious imaging features: heterogeneous, enhancement, irregular margins, necrosis, splenic parenchymal or vascular invasion, substantial enlargement. ¶Indeterminate imaging features: heterogeneous, intermediate attenuation (>20 HU), enhancement, smooth margins. #Follow-up MRI in 6 and 12 months.

characteristics of benign and malignant splenic masses overlap and the nature of most incidentally discovered splenic masses is never determined. Literature describing the “characteristic” findings of splenic masses is limited and often suffers from selection bias based on the few that are histologically characterized. By providing a reasonable differential diagnosis, the radiologist can help assess the nature and importance of the finding to assist the clinician in placing it in clinical context. Some features compel the radiologist to recommend that incidental splenic masses should undergo prompt additional evaluation, whereas other findings should lead to imaging follow-up. Biopsy of splenic masses is uncommonly recommended, such as for suspected angiosarcoma or in a patient with a history of a known malignancy [3,4]. Using other noninvasive imaging modalities, especially MRI and including PET and ultrasound, may help select high-risk patients for splenic biopsy [4].

The Incidental Findings Committee II’s guidance for managing incidentally detected splenic masses is shown in the flowchart in Figure 1. The algorithm takes into account the imaging characteristics of the splenic mass, the findings on prior imaging examinations, and the patient’s clinical history.

### Diagnostic Criteria for Specific Lesions

A splenic mass detected in an asymptomatic patient is an incidental lesion that poses a diagnostic dilemma. The typical incidentally discovered splenic mass is a solid or mostly solid lesion that is hypoattenuating on CT, low signal intensity on T1-weighted images, and intermediate to mildly increased signal intensity on T2-weighted

images. Most incidentally discovered splenic lesions are relatively hypovascular but can show variable enhancement on postcontrast images. Although the overlap of imaging features often precludes a definitive diagnosis during the initial assessment, the radiologist plays a central role in the patient’s triage and subsequent work-up. From a practical management standpoint, characterization of an incidentally discovered splenic lesion into one of several broad disease categories aids the referring clinician’s decision making. For example, is the incidentally discovered splenic lesion more likely to be due to metastasis or lymphoma, or caused by a primary, and typically benign, splenic neoplasm?

In a patient with a history of a primary neoplasm with a tendency to metastasize to the spleen, an incidentally discovered splenic lesion >1 cm should be suspected to be a metastasis. Even in the face of a known neoplasm, a very small lesion (<1 cm) is likely benign. Despite the lack of literature specific to incidentally discovered small splenic lesions, corroborative evidence can be drawn from the literature regarding liver lesions [5-7]. Although masses >1 cm may be benign, imaging characteristics that favor metastasis include heterogeneity of the lesion, poorly defined or infiltrating margins, and multiplicity. If these imaging features are present, further evaluation with PET or biopsy may be considered. One entity often confused with metastases is lymphangiomatosis. The best way to avoid this pitfall is to perform MRI. On MRI, multiple lymphangiomas have low signal intensity on T1-weighted images, high signal intensity on T2-weighted images, and do not enhance; they are often

subcapsular in location and multiloculated as well [2,3]. See further description of the imaging findings of lymphangiomas below. Metastases have low signal intensity on T1-weighted images, relatively high signal intensity on T2-weighted images, and are heterogeneous, especially on T2-weighted images; metastases are often poorly margined and enhance heterogeneously.

Isolated splenic lymphoma, defined as splenic tumor without accompanying regional or distant lymphadenopathy, is uncommon. When present, the isolated lymphomatous mass is usually large, and it may completely obliterate the spleen, filling the entire left upper quadrant. In such cases, the differential diagnosis includes a large, exophytic gastric gastrointestinal stromal tumor (GIST). When splenic lymphoma is multifocal, the spleen is generally enlarged and there is typically coexisting regional and/or distant lymphadenopathy. Lymphomatous masses are often poorly margined and on CT are slightly hypoenhancing relative to the normal, adjacent spleen. In these cases, biopsy of the splenic mass or a nodal mass can usually establish the diagnosis, if required for management.

If there are no findings or history to suggest that one or more splenic masses are metastatic, such as multiple, poorly defined heterogeneous lesions, known lymphoma, or a large mass distorting the spleen, a primary benign neoplasm should be considered, with some of the more common entities including cyst, hemangioma, hamartoma, and lymphangioma. The features of a simple cyst on CT include a well-defined, low-attenuation lesion with a thin or imperceptible wall. On MR, simple cysts are hypointense on T1-weighted images and hyperintense on T2-weighted images and have well-defined walls without nodules or papillary excrescences. Cysts are water attenuation on CT, have low signal on T1, high signal on T2-weighted pulse sequences (equal to cerebrospinal fluid (CSF) and a normal gallbladder), and do not enhance [3,4]. Some water to near-water attenuation masses have dense, peripheral calcifications. These are either old splenic hematomas or post-traumatic cysts. When thick, dense wall calcification is present ( $>5$  mm and often 1 cm to 1.5 cm in thickness), these can confidently be diagnosed as benign. Cysts from *Echinococcus granulosus* (which often have thick, calcified walls) isolated to the spleen (without lung or liver involvement) virtually never occur [8].

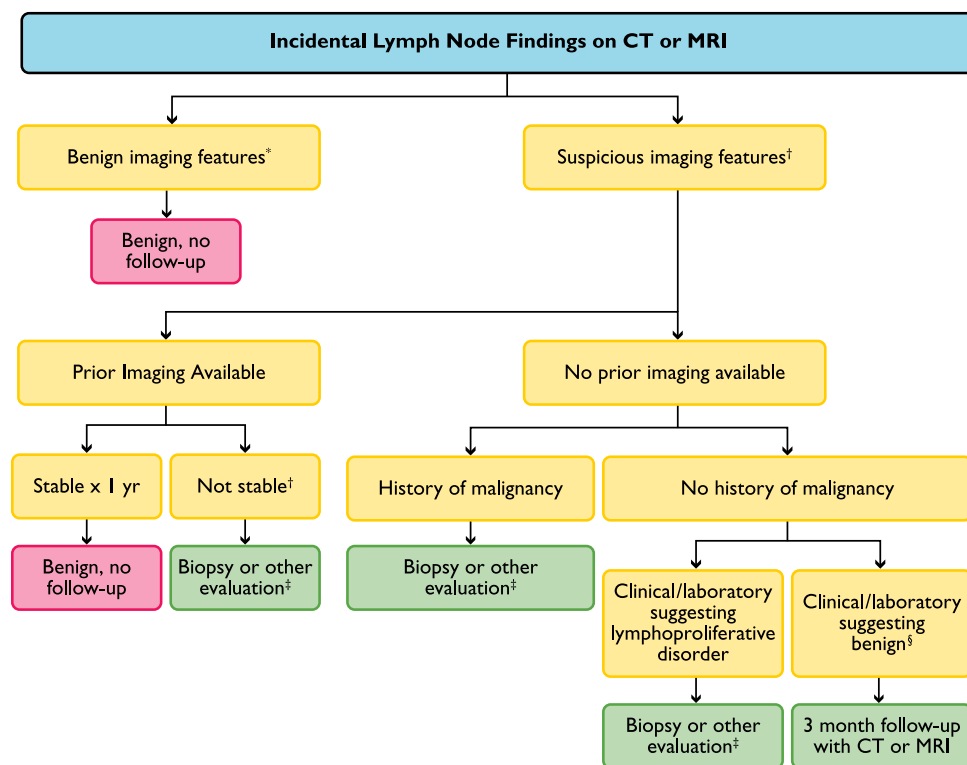
Hemangioma is the most common benign primary vascular neoplasm of the spleen [2]. However, splenic hemangiomas rarely, if ever, show the typical centripetal enhancement seen in similar hepatic lesions, but they can show delayed enhancement within the solid portions, secondary to slow filling of the vascular channels [2]. Most hemangiomas are hypoattenuating on noncontrast CT, iso- to hypointense on T1-weighted images, and hyperintense on T2-weighted images, and variably enhance on both CT and MR [9].

Hamartomas are iso- or hypoattenuating on unenhanced CT scans and are typically hyperintense relative to the spleen on T2-weighted images. Heterogeneous enhancement is seen on CT or MRI during early post-contrast images, whereas more uniform, prolonged enhancement is seen on delayed images [2,4,10-12].

CT features of lymphangioma and lymphangiomatosis include splenomegaly, with single or multiple areas of low attenuation. As previously noted, MR is the best imaging study to identify this entity. On MRI, lymphangioma typically appears as a multicystic lesion, although some of its components can appear hyperintense on T1-weighted images because of their proteinaceous or hemorrhagic contents [2]. Lymphangiomas are sharply margined, usually subcapsular, and typically do not enhance on postcontrast series [2,3].

Other vascular tumors of the spleen include those of variable or uncertain biologic behavior, such as littoral cell angioma, hemangioendothelioma, and hemangiopericytoma. These tumors are exceedingly rare. On CT, all of these lesions may appear as hypoattenuating, solid lesions, both before and after contrast media. On MRI, littoral cell angioma and hemangioendothelioma are typically hypointense on both T1- and T2-weighted images because of the presence of hemosiderin in the lesions, whereas hemangiopericytoma is hypointense on T1-weighted images and hyperintense on T2-weighted images [2]. Because all of these lesions can show heterogeneous and variable enhancement during postcontrast CT or MRI [2,3,13], they may be regarded as having some of the suspicious imaging features noted in the accompanying flowchart (Fig. 1). Further evaluation with PET or biopsy is recommended for incidentally discovered splenic masses with these features. PET/CT can be used to discriminate between benign and malignant splenic masses in patients with known F18-FDG avid malignancy [14].

The reluctance to perform needle aspiration or biopsy of a splenic mass has been attributed to splenic vascularity and the consequent risk of bleeding because of the very thin capsule, together with the difficulty in access due to intervening pleura, lung, or the splenic flexure of the colon [15]. However, several studies have shown the usefulness and safety of splenic biopsy [4,15-17]. A specific diagnosis can be obtained in up to 91% of cases [16]. The biopsy method usually used in these series was a fine needle aspiration for cytopathology rather than a core needle biopsy for surgical pathology, but core biopsies may be performed. An alternative to percutaneous fine needle aspiration is one guided by endoscopic ultrasound. The most common complication is bleeding. Rates of hemorrhage have been documented in the literature ranging from 0% to 2% and usually result from biopsy of vascular lesions [4,16]. Before any intervention of the spleen is contemplated, a surgical consult is essential for backup.



**Fig 2.** \*Benign imaging features: normal short-axis diameter ( $<1$  cm in retroperitoneum), normal architecture (elongated, fatty hilum), normal enhancement, normal node number. †Abnormal imaging features: enlarged short-axis diameter ( $\geq 1$  cm in retroperitoneum), architecture (round, indistinct hilum), enhancement (necrosis/hypervascular), increased number (cluster of  $\geq 3$  lymph nodes in single nodal station or cluster of  $\geq 2$  lymph nodes in  $\geq 2$  regions). ‡Nonneoplastic disease: eg, infection, inflammation, connective tissue. §Other evaluation (PET/CT, nuclear scintigraphy [MIBG], endoscopic ultrasound).

Splenic masses that are symptomatic or metastatic and found during staging for a malignancy cannot be considered incidental and should be managed as a possible manifestation of the condition being evaluated. Also, malignant splenic masses are rarely incidental [4]. Angiosarcoma is the most common nonlymphoid malignant primary tumor of the spleen [2,10]. Patients are usually symptomatic, presenting with fever, fatigue, and weight loss [4]. On CT or MRI, these tumors often result in splenomegaly and can appear as ill-defined masses with solid and cystic components; their variable composition and enhancement reflecting areas of necrotic degeneration and hemorrhage [2,4].

In summary, most incidentally detected splenic masses are benign. Although a definitive diagnosis based solely on the imaging findings is possible in select cases, this is the exception. In most cases, the imaging findings are nonspecific and further evaluation may often be indicated. Because there are few pathologically proven published cases, there is a paucity of literature regarding management of incidentally detected splenic lesions based on their imaging findings. However, application of specific imaging criteria can help determine if a lesion is more likely to be malignant and should undergo further prompt evaluation with PET or biopsy. For the remaining indeterminate splenic lesions that are incidentally discovered, a follow-up MRI in 6 months, and if stable in 12 months, is a reasonable approach to aid in management.

## INCIDENTAL FINDINGS OF LYMPH NODES

The routine detection of normal-sized abdominal and pelvic lymph nodes by CT and MRI is primarily due to the remarkable evolution in multidetector CT and high-resolution MRI technology. Therefore, because identifying lymph nodes is expected, the radiologist plays an important role in management by suggesting which incidentally identified lymph nodes require no further evaluation and which should undergo prompt additional evaluation and/or follow-up.

The committee's suggested guidance for managing incidentally detected lymph nodes is shown in the flowchart in Figure 2 and is based on a combination of the imaging characteristics of the lymph node, prior imaging examinations, the patient's clinical history, and their risk for developing clinically important lymph nodes. The recommendations may be modified, depending on comorbidities, history, and presentation.

Although additional imaging modalities (such as ultrasound and PET) are available to further evaluate incidentally discovered lymph nodes, percutaneous or surgical biopsy remains the reference standard for diagnosis. However, biopsies are associated with variable postprocedural morbidity and mortality depending on the lymph node location, technique, and the patient's comorbidities.

### Imaging Characterization and Workup Algorithm

In the large majority of cases, lymph nodes discovered incidentally during abdominal-pelvic CT or MRI are normal, and if the imaging characteristics are normal, no



additional evaluation or follow-up imaging is recommended. The imaging parameters to assess include the lymph node's size, morphology, attenuation/signal, enhancement, location and number. A few studies have attempted to define the size of a normal lymph node in the abdomen [18] and pelvis [19]. One study evaluated lymph nodes in trauma patients by measuring the short-axis of lymph nodes in several positions, including the retrocrural space, paracardiac, gastrohepatic ligament, upper para-aortic region, portacaval space, porta hepatis and lower para-aortic region [18]. This study did not assess mesenteric lymph nodes or the number of lymph nodes as a factor that might determine whether the lymph nodes were abnormal. The proposed size criteria were based on the short-axis diameter as it has been well established as more reproducible than the long-axis measurement [20], and a better predictor of metastatic involvement and treatment response [21,22]. A more simplified approach set forth by the Response Evaluation Criteria in Solid Tumours (RECIST) Working Group uses a short-axis diameter of  $\geq 1$  cm as an acceptable and practical discriminatory value between normal and abnormal lymph nodes [23,24]. Based on these references and the consensus of the Incidental Findings Committee II, a short-axis diameter of  $\geq 1$  cm in the retroperitoneum is recommended to discriminate between normal-sized and suspiciously enlarged nodes, as illustrated in the lymph node flowchart (Fig. 2). In other positions, this may also be appropriate; however, there is little evidence in the literature to support the use of a short-axis threshold of 1 cm elsewhere, especially in the retrocrural or porta hepatis spaces, where abnormal lymph nodes may be smaller. Nevertheless, many mildly enlarged nodes are still of no clinical importance, and the additional imaging parameters listed above can be used to help decide on management.

Since normal-sized nodes may also harbor disease, lymph node architecture and number should be assessed. Normal lymph nodes typically have an elongated appearance with a central fatty hilum, and lymph nodes that lack these architectural features may be considered possibly abnormal. Additionally, because most lymph nodes enhance after infusion of intravenous contrast material because of their rich blood supply, the relative degree of lymph node enhancement can be compared to enhancement of other nodes in the abdomen and pelvis. Profound hypervascularity or necrosis signify an alteration of the normal blood flow and markedly increase the probability that the node is abnormal. Profound alterations in size or architecture need not be present for lymph nodes to be considered abnormal. For example, patients with low-grade lymphoma are often found to have multiple nonenlarged nodes scattered throughout multiple regions of the abdomen and pelvis. In such cases, diagnosis is often left to the radiologist's gestalt or personal experience. In an attempt to provide a more quantitative anal-

ysis, the Incidental Finding Committee II has developed the following scheme as rough guidance, based on a review of the available radiology literature and personal experience: Although there is currently no specific conclusion that can be drawn from the radiology literature on what constitutes an abnormal number of lymph nodes in the abdomen and pelvis, the consensus of the Incidental Findings Committee II is that a cluster of  $\geq 3$  lymph nodes in a single nodal station or a cluster of  $\geq 2$  lymph nodes in  $\geq 2$  regions (ie, gastrohepatic ligament, retroperitoneum, and mesentery) may be considered suspicious. The committee recognizes that a qualitative assessment of the number of lymph nodes may supplement the recommendations discussed above.

Although the above criteria may be used to triage patients with suspicious lymph nodes, the abnormal lymph nodes often cannot be specifically characterized because they may represent various neoplastic, infectious, inflammatory, autoimmune or idiopathic conditions [25-29]. Nevertheless, the distribution of suspicious lymph nodes can be used to further direct management. If a patient has an abnormal number or appearance of lymph nodes, and clinical and laboratory abnormalities suggest a possible lymphoproliferative disorder, an image-guided biopsy of an accessible, representative lymph node is recommended. Although PET may also be considered, its relative lack of specificity and higher cost make it a less efficient alternative.

If a patient has multiple abnormal lymph nodes but no overt clinical or laboratory abnormalities suggesting a lymphoproliferative disorder, a short-term follow-up CT or MRI is recommended. Although there is no consensus in the literature regarding the optimal short-term follow-up interval, the committee recommends imaging follow-up in about 3 months, allowing time for evaluating treatment response, for example, if antibiotics have been given, and for other medical evaluation.

In a patient with an underlying non-neoplastic condition, the incidental finding of an isolated abnormal lymph node or nodal group(s) may be considered as most likely to be secondary to this condition. In these cases, a short-term follow-up CT or MRI is recommended to reassess the lymph nodes after treatment. For example, in patients with pancreatitis, after resolution, abnormal upper abdominal lymph nodes typically normalize. However, other conditions, such as inflammatory bowel disease, may lead to long-standing lymph node enlargement.

For an incidental nodal finding in a patient who has a condition that is unlikely to cause adenopathy or has a neoplasm that is unlikely to metastasize to the regional or distant lymph nodes, any available relevant prior imaging and medical history should be reviewed. There is no consensus in the literature regarding the optimal period to follow enlarged abdominal and pelvic lymph nodes; however, if the abnormal lymph node or nodal group(s)

has been unchanged for a period of one year, the committee believes that the finding may be considered stable and benign with no further follow-up imaging or evaluation recommended. However, if a change based on the previously discussed criteria is detected, further evaluation should be considered with PET or percutaneous, image-guided biopsy.

If a patient has an abnormal lymph node or nodal group(s) and no known malignancy, but no prior imaging is available, a short-term follow-up evaluation of the abnormal lymph node or nodal group may be helpful. If a patient has a prior history of a malignancy that has a tendency to metastasize to an area of observed adenopathy, then this cannot be considered an incidental finding and should be managed as appropriate for that condition.

The finding of regional adenopathy in the presence of an overt inflammatory process usually does not pose a diagnostic dilemma. However, it may be difficult to determine the importance of nodal enlargement when other inflammatory conditions are present, including primary biliary cirrhosis, sarcoidosis, or mastocytosis [19,23,24], or other systemic diseases such as rheumatoid arthritis or systemic lupus erythematosus [25,26].

Mesenteric lymph node enlargement may be caused by sclerosing mesenteritis, which is also known by other names, including mesenteric panniculitis and mesenteritis. It is frequently asymptomatic and detected incidentally. However, it may also be associated with vague symptoms, such as generalized abdominal discomfort. It is associated with a variable degree of encapsulated infiltration of the mesenteric fat and a preserved rim of fat surrounding the adjacent vessels, the "fat halo sign" [30], which can be used to help differentiate it from metastatic adenopathy, lymphoma, and desmoid tumor. Because it is relatively common, sclerosing mesenteritis may also coexist with malignant or other etiologies of adenopathy.

In summary, most lymph nodes identified during abdominal-pelvic CT or MRI are normal. Lymph nodes may be considered suspicious for being abnormal based on size, morphology, attenuation/signal, enhancement characteristics, and number. Lymph nodes that do not meet normal criteria may be caused by numerous neoplastic, inflammatory, infectious, and autoimmune conditions. If the etiology or stability of abnormal lymph nodes cannot be determined during abdominal-pelvic CT or MRI examination or by correlating to the patient's history or prior imaging, a short-term follow-up examination in about 3 months is recommended versus consideration of fine-needle aspiration or core biopsy, if warranted by co-morbidities and other clinical and laboratory findings.

## TAKE-HOME POINTS

- If there are no suggestions that one or more splenic masses are metastatic, a primary benign condition

should be considered, including cyst, hemangioma, hamartoma, and lymphangioma.

- The committee recommends that a short-axis diameter of  $\geq 1$  cm be used to discriminate between normal-sized and suspiciously enlarged nodes.
- The consensus of the committee is that a cluster of  $\geq 3$  lymph nodes in a single nodal station or a cluster of  $\geq 2$  lymph nodes in  $\geq 2$  regions may be considered suspicious.
- If a patient has multiple abnormal lymph nodes, but no overt clinical or laboratory abnormalities suggesting a lymphoproliferative disorder, a short-term follow-up CT or MRI is recommended in about 3 months.
- If an abnormal lymph node or nodal group(s) is unchanged for a period of 1 year, the committee believes that the finding may be considered benign with no further follow-up imaging recommended.

## ACKNOWLEDGMENTS

The authors thank David Kurth of the ACR staff, who helped support and coordinate the activities that led to this manuscript, and Drs Joel Platt and Mark Baker for their review and suggestions.

## APPENDIX

### Committee Members

Incidental Findings Committee II: Lincoln L. Berland, MD, chair.

Spleen and Lymph Node Subcommittee: Matthew T. Heller, MD, chair, Mukesh Harisinghani, MD, Jeffrey D. Neitlich, MD, Paula Yeghiayan, MD

Ex Officio: James A. Brink, MD, chair, ACR Body Imaging Commission.

## REFERENCES

1. Berland LL. Overview of white papers of the ACR Incidental Findings Committee II on ovarian and paraovarian, vascular, splenic, nodal, gallbladder and biliary findings. *J Am Coll Radiol* 2010;10:672-4.
2. Abbott RM, Levy AD, Aguilera NS, et al. From the archives of the AFIP primary vascular neoplasms of the spleen: radiologic-pathologic correlation. *Radiographics* 2004;24:1137-63.
3. Urrutia M, Mergo PJ, Ros LH, et al. Cystic masses of the spleen: radiologic-pathologic correlation. *Radiographics* 1996;16:107-29.
4. Ahmed S, Horton KM, Fishman EK. Splenic incidentalomas. *Radiol Clin N Am* 2011;49:323-47.
5. Schwartz LH, Gandras EJ, Colangelo S, et al. Prevalence and importance of small hepatic lesions found at CT in patients with cancer. *Radiology* 1999;210:71-4.
6. Jain HJ, Lim HK, Lee WJ, et al. Small hypoattenuating lesions in the liver on single-phase helical CT in preoperative patients with gastric and colorectal cancer: prevalence, significance, and differentiating features. *J Comput Assist Tomogr* 2002;26:718-24.
7. Gore RM, Newmark GM, Thakrar KH, et al. Hepatic incidentalomas. *Radiol Clin N Am* 2011;49:291-322.

8. Ilica AT, Kocaoglu M, Zeybek N, et al. Extrahepatic abdominal hydatid disease caused by *Echinococcus granulosus*: imaging findings. *AJR Am J Roentgenol* 2007;189:337-43.
9. Vilanova JC, Capdevila A, Aldoma J, Delgado E. Splenic epithelioid hemangioma: MR findings. *AJR Am J Roentgenol* 1994;163:747-8.
10. Lee H, Maeda K. Hamartoma of the Spleen. *Arch Pathol Lab Med* 2009;133:147-51.
11. Ramani M, Reinhold C, Semelka R, et al. Splenic hemangiomas and hamartomas: MR imaging characteristics of 28 lesions. *Radiology* 1997;202:166-72.
12. Ohtomo K, Fukuda H, Mori K, Minami M, Itai Y, Inoue Y. CT and MR appearances of splenic hamartoma. *J Comput Assist Tomogr* 1992;16:425-8.
13. Bhavsar T, Wang C, Huang Y, et al. Littoral cell angiomas of the spleen associated with solid pseudopapillary tumor of the pancreas. *World J Gastrointest Pathophysiol* 2011;2:53-6.
14. Metser U, Miller E, Kessler A, et al. Solid splenic masses: evaluation with F18-FDG PET/CT. *J Nucl Med* 2005;46:52-9.
15. Venkataramu NK, Gupta S, Sood BP, et al. Ultrasound guided fine needle aspiration biopsy of splenic lesions. *Br J Radiol* 1999;72:953-6.
16. Lucey BC, Boland GW, Maher MM, et al. Percutaneous nonvascular splenic intervention: a 10-year review. *AJR Am J Roentgenol* 2002;179:1591-6.
17. Keogan MT, Freed KS, Paulson EK, et al. Imaging-guided percutaneous biopsy of focal splenic lesions: update on safety and effectiveness. *AJR Am J Roentgenol* 1999;172:933-7.
18. Dorfman RE, et al. Upper abdominal lymph nodes: criteria for normal size determined with CT. *Radiology* 1991;180:319-22.
19. Grubnic S, et al. MR evaluation of normal retroperitoneal and pelvic lymph nodes. *Clin Radiol* 2002;57:193-200; discussion 201-4.
20. Glazer GM, et al. Normal mediastinal lymph nodes: number and size according to American Thoracic Society mapping. *AJR Am J Roentgenol* 1985;144:261-5.
21. Matsuoka H, et al. Morphological characteristics of lateral pelvic lymph nodes in rectal carcinoma. *Langenbecks Arch Surg* 2007;392:543-7.
22. Schwartz LH, et al. Measuring tumor response and shape change on CT: esophageal cancer as a paradigm. *Ann Oncol* 2006;17:1018-23.
23. Eisenhauer EA, et al. New response evaluation criteria in solid tumours: revised RECIST guideline (version 1.1). *Eur J Cancer* 2009;45:228-47.
24. van Persijn van Meerten EL, Gelderblom H, Bloem JL. RECIST revised: implications for the radiologist. A review article on the modified RECIST guideline. *Eur Radiol* 2010;20:1456-67.
25. Outwater E, Kaplan MM, Bankoff MS. Lymphadenopathy in primary biliary cirrhosis: CT observations. *Radiology* 1989;171:731-3.
26. Fazzi P, et al. Sarcoidosis: single bulky mesenteric lymph node mimicking a lymphoma. *Sarcoidosis* 1995;12:75-7.
27. Ben Romdhane K, Ben Romdhane N, Ben Younes MR, Ayadi S, Ben Ayed M. Systemic mastocytosis. A case report. *Arch Anat Cytol Pathol* 1990;38:100-3.
28. Calguneri M, et al. Frequency of lymphadenopathy in rheumatoid arthritis and systemic lupus erythematosus. *J Int Med Res* 2003;31:345-9.
29. Kitsanou M, et al. Extensive lymphadenopathy as the first clinical manifestation in systemic lupus erythematosus. *Lupus* 2000;9:140-3.
30. Sabate JM, Torrubia S, Maideu J, Franquet T, Monill JM, Perez C. Sclerosing mesenteritis: imaging findings in 17 patients. *AJR Am J Roentgenol* 1999;172:625-9.



Credits awarded for this enduring activity are designated "SA-CME" by the American Board of Radiology (ABR) and qualify toward fulfilling requirements for Maintenance of Certification (MOC) Part II: Lifelong Learning and Self-assessment.